Journal of Pediatric Surgery 51 (2016) 2033–2038

Contents lists available at ScienceDirect

Journal of Pediatric Surgery

journal homepage: www.elsevier.com/locate/jpedsurg

Intercostal nerve cryoablation versus thoracic epidural catheters for postoperative analgesia following pectus excavatum repair: Preliminary outcomes in twenty-six cryoablation patients☆

Benjamin A. Keller [a,*], Sandra K. Kabagambe [a], James C. Becker [a], Y. Julia Chen [a], Laura F. Goodman [a], Julianna M. Clark-Wronski [b], Kenneth Furukawa [b], Rebecca A. Stark [a,c], Amy L. Rahm [a,c], Shinjiro Hirose [a,c], Gary W. Raff [a,c]

[a] Davis Health System, Department of Surgery, University of California, Sacramento, CA
[b] Davis Health System, Department of Anesthesia, University of California, Sacramento, CA
[c] Department of Surgery, Shriners Hospital for Children – Northern California, Sacramento, CA

ARTICLE INFO

Article history:
Received 15 August 2016
Accepted 12 September 2016

Key words:
Pectus excavatum
Nuss procedure
Cryoablation
Epidural analgesia
Pain management

ABSTRACT

Background: Multimodal pain management strategies are used for analgesia following pectus excavatum repair. However, the optimal regimen has not been identified. We describe our early experience with intercostal cryoablation for pain management in children undergoing the Nuss procedure and compare early cryoablation outcomes to our prior outcomes using thoracic epidural analgesia.
Methods: A multi-institutional, retrospective review of fifty-two patients undergoing Nuss bar placement with either intercostal cryoablation ($n = 26$) or thoracic epidural analgesia ($n = 26$) from March 2013 to January 2016 was conducted. The primary outcome was hospital length of stay. Secondary outcomes included telemetry unit monitoring time, total intravenous narcotic use, duration of intravenous narcotic use, and postoperative complications.
Results: Patients who underwent intercostal cryoablation had a significant reduction in the mean hospital length of stay, time in a monitored telemetry bed, total use of intravenous narcotics, and the duration of intravenous narcotic administration when compared to thoracic epidural patients. Cryoablation patients had a slightly higher rate of postoperative complications.
Conclusion: Intercostal cryoablation is a promising technique for postoperative pain management in children undergoing repair of pectus excavatum. This therapy results in reduced time to hospital discharge, decreased intravenous narcotic utilization, and has eliminated epidurals from our practice.
Level of evidence: Retrospective study – level III.

© 2016 Elsevier Inc. All rights reserved.

Pectus excavatum is the most common chest wall deformity, with an estimated occurrence of 1 in 400 to 1 in 1000 live births, and an approximate 6:1 predilection for males [1]. The deformity is characterized by a posterior curvature of the sternum and lower costal cartilage resulting in a "funnel chest" appearance. The clinical manifestations of pectus excavatum vary depending on the severity, but can include cardiopulmonary symptoms (exercise intolerance, shortness of breath), chest wall pain, poor endurance, and cosmetic concerns leading to psychosocial difficulties [2,3]. Historically, patients with pectus excavatum underwent the Ravitch procedure consisting of subperichondrial cartilage resection and sternal osteotomy [4]. In 1998, Donald Nuss introduced a minimally invasive alternative utilizing retrosternal placement of a contoured bar to produce an outward force on the sternum [5]. While the Nuss procedure minimizes the operative time and incision size, it is associated with significant postoperative pain comparable to the open repair [6,7]. Several approaches to postoperative pain management have been attempted, including using thoracic epidurals, paravertebral regional blocks, intercostal blocks, intercostal infusion catheters, patient-controlled analgesia, and multimodal anesthesia, however an optimal regimen has not yet been established [8–13]. Typically, narcotics are used as a primary modality for pain control with epidurals, anti-inflammatories, and muscle relaxants as adjuncts. Despite different techniques and the development of multifaceted pain management strategies; pain control and treatment of complications such as nausea and constipation because of around-the-clock narcotic use remain a significant challenge after the Nuss procedure.

Cryotherapy has been used for decades to treat pain syndromes including facial neuralgias, peripheral neuropathies and facet joint pain [14]. In the 1970s, this technique was expanded to patients who

☆ Disclosure: Gary W. Raff is a consultant for Atricure® (Mason, OH).

* Corresponding author at: Davis Health System, Department of Surgery, University of California, 2315 Stockton Blvd, OP512, Sacramento, CA 95817. Tel.: +1 916 734 2724.
E-mail address: bakeller@ucdavis.edu (B.A. Keller).

http://dx.doi.org/10.1016/j.jpedsurg.2016.09.034
0022-3468/© 2016 Elsevier Inc. All rights reserved.

underwent a thoracotomy for postoperative pain control [15]. The use of cryotherapy in these patients has been shown to decrease postoperative opioid usage and improve pulmonary mechanics [16–18]. Despite these promising findings, cryoablative analgesia was not adopted for use in the Nuss procedure until recently. In early 2015, the Food and Drug Administration (FDA) approved the first commercially available cryoablation probe (CryoICE®, AtriCure, Mason, OH) for temporary ablation of peripheral nerves, generating renewed interest in applying this technique to managing postoperative pain [19].

Given the prior success of cryoanalgesia in adult patients undergoing thoracic surgery and the challenges associated with pain control in children undergoing the Nuss procedure, we began using cryoablation as the foundation of our postoperative pain management strategy. The purpose of this study is to describe our method of intercostal nerve cryoablation and report the results of our early experience with it as a novel technique for pain management in children undergoing the Nuss procedure. These results are compared to a historical control group of patients that were managed with thoracic epidural catheters.

1. Methods

1.1. Retrospective review and data collection

After obtaining institutional review board (IRB) approval, a multi-institution, retrospective review of all patients who underwent Nuss bar placement for pectus excavatum repair between March 1, 2013 and January 31, 2016 was conducted. No patients were excluded from analysis. The patient's age, gender, Haller index, American Society of Anesthesiologists (ASA) physical status classification, and the indication for pectus repair were recorded. Operative, hospital, and outpatient follow-up data were collected. The primary outcome was hospital length of stay (LOS) after surgery. Secondary outcomes included operative time, telemetry unit monitoring time, total amount of intravenous (IV) narcotic use, and the duration of IV narcotic use. Narcotic use at the first follow-up appointment, subjective chest wall complaints at the three-month follow-up appointment and any procedure related complications were reviewed.

1.2. Thoracic epidural management

Patients in the thoracic epidural group were brought to the operating room and following premedication with fentanyl and midazolam, underwent thoracic epidural placement prior to the induction of anesthesia. Postoperatively, hydromorphone with or without bupivacaine was used for the epidural infusion. Epidural infusions, including changes to the infusion rate and epidural boluses were managed by anesthesiologists with input from the surgical team until the time of removal. Epidural catheters were removed between postoperative days two and three.

1.3. Intercostal nerve cryoablation

Early in our experience with cryoablation, the procedure was performed after the Nuss bar was placed. We altered our approach midway through the study period and began performing cryoablation prior to Nuss bar placement. To perform the cryoablation, a 5-mm 30-degree thoracoscope is placed in the thoracic cavity for direct visualization of the thoracic wall and to monitor ice crystal formation (Fig. 1). Utilizing the same incisions used for the Nuss bar placement, a subcutaneous tunnel is bluntly created up to the third intercostal space. The Atricure CryoICE® cryoablation probe (Mason, OH) is inserted through the subcutaneous tunnel, and its position confirmed by thoracoscopy. The probe is cooled to −60 degrees Celsius for two minutes. Proper position of the probe is confirmed by observing muscle fasciculations in the intercostal space. After the ablation cycle is complete, the probe is warmed to ambient temperature and allowed to release from the nerve without traction. Care is taken to avoid any other injury to the intercostal nerves and to only dissect bluntly in the region of the nerve to avoid disturbing the epineurium. This procedure is repeated in the fourth, fifth, sixth, and seventh intercostal spaces bilaterally.

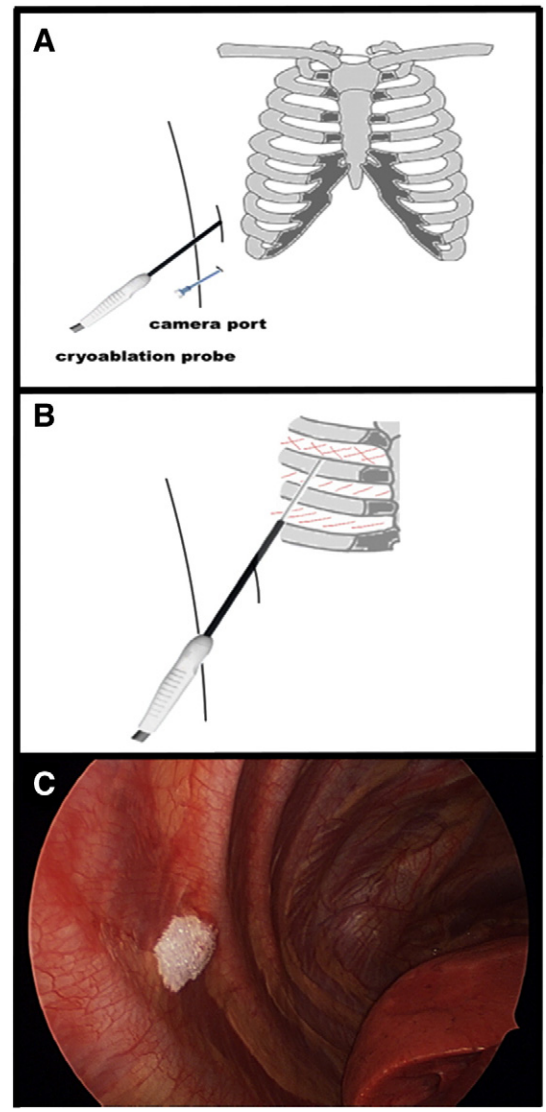

Fig. 1. The Atricure CryoICE probe is tunneled subcutaneously to the third intercostal space and cryoablation is performed. The procedure is repeated in the fourth, fifth, sixth, and seventh intercostal spaces bilaterally (A&B). A 5-mm 30-degree scope is placed in the thoracic cavity to monitor ice crystal formation during cryoablation (C).

1.4. Postoperative pain management

In both the thoracic epidural and the cryoablation groups, patients were managed with similar multi-modal pain management strategies. All children were started on patient controlled IV narcotic analgesics and 48 to 72 h of scheduled IV non-steroidal anti-inflammatories (ketorolac) immediately postoperatively. In addition to narcotics and anti-inflammatory medications, benzodiazepines (diazepam) were utilized for muscle spasms as needed. In the cryoablation group, gabapentin was started on postoperative day two to prevent the development of neuropathic chest wall pain. As pain improved and patients had adequate oral intake, children were transitioned to

Table 1
Demographics.

	Epidural ($n = 26$)	Cryoablation ($n = 26$)	*P*-value
Mean age at repair (SD)	15.26 (1.61)	15.59 (1.53)	0.4665
Gender			
Male (%)	23 (88%)	20 (77%)	0.2715
Female (%)	3 (12%)	6 (23%)	
Mean Haller index (SD)	3.80 (1.00)	4.23 (1.36)	0.2503
Mean ASA physical status (range)	1 (1–2)	1 (1–2)	1.0000
Indications for pectus repair			
Exercise intolerance (%)	20 (77%)	21 (81%)	0.7342
Chest wall pain (%)	20 (77%)	14 (54%)	0.0803
Body image (%)	17 (65%)	10 (38%)	0.0520

scheduled ibuprofen, IV narcotics were weaned, and oral narcotics were started at the discretion of the operative team.

Seven patients in the epidural group and 24 patients in the cryoablation group were also managed with local infusion catheters (On-Q pumps). Two catheters were tunneled in the subcutaneous tissue of the anterior chest wall with one catheter placed above the level of the Nuss bar and one catheter placed below. Postoperatively, 0.2% ropivacaine was infused at a rate of 3–6 mL per hour. Local infusion catheters were removed on postoperative day two to three.

1.5. Institutional policy and discharge readiness

The postoperative policy at both institutions states that pediatric patients who require a continuous narcotic infusion (PCA or otherwise), or thoracic epidural infusion must be in a monitored setting (telemetry unit). Our practice pattern has evolved such that patients are considered to be ready for discharge if they meet the following criteria. First, they have not received IV narcotics in 24 h and their pain control is adequate with oral medication. Second, they do not need active treatment for nausea or constipation and lastly they do not have any other contraindications to going home. Patients were typically discharged with around-the-clock ibuprofen, oral narcotics, and diazepam as needed for pain and muscle spasms. Patients who underwent cryoablation were continued on 300 mg gabapentin daily to prevent neuropathic pain.

1.6. Statistical analysis

Statistical analysis was performed with R version 3.2.3 (R Core Team (2015) Vienna, Austria). Data are expressed as mean ± standard deviation where appropriate. Continuous variables were compared with two sample Welch's t-tests. Discrete variables were analyzed with chi-squared tests. Multivariate linear regression was used to determine predictors of primary and secondary outcomes. Covariates for regression were identified by the 10% change in estimate approach. $P \leq 0.05$ was considered significant for all tests.

2. Results

Fifty-two patients who underwent Nuss bar placement from March 1, 2013 until January 31, 2016 were included. Twenty-six patients were managed with thoracic epidurals, while twenty-six patients were managed with bilateral intercostal nerve cryoablation. Both groups displayed similar mean ages and Haller indices of 15.26 years and 3.80 in the epidural group and 15.59 years and 4.23 in the cryoablation group (Table 1). In addition, there were no statistically significant differences in the gender, ASA class, or the indication for pectus repair between groups.

Cryoablation added approximately 20 min to the surgical time with the average time for Nuss bar placement with cryoablation totaling 114.2 min compared to 94.3 min for the epidural group. In addition, the total time spent in the operating room was also 20 min longer on average in the cryoablation group (Table 2). There were no differences in estimated blood loss or intraoperative complications between groups. Two patients in the cryoablation group had two Nuss bars placed while none of the patients in the epidural group had multiple Nuss bars placed. Seven patients who underwent thoracic epidural placement and twenty-four patients who underwent cryoablation also had subcutaneous local anesthetic infusion catheters placed.

The mean length of stay for patients undergoing pectus repair with intercostal cryoablation was 3.47 ± 0.83 days, which was significantly shorter than the 5.79 ± 0.93 days in the epidural group ($p < 0.001$, Table 3). Sixty-two percent of patients in the cryoablation group were discharged on or before hospital day three compared to 4% of patients in the epidural group (Fig. 2). Patients in the cryoablation group were also downgraded from a monitored unit quicker at an average of 1.88 days compared to 3.73 days in the epidural group ($p < 0.001$). The total dose of IV narcotics (morphine equivalents) administered via both patient controlled analgesia and IV bolus was significantly less in the cryoablation group (49.03 mg) compared to the epidural group (119.8 mg, $p = 0.0011$) Additionally, 88% of patients in the cryoablation group discontinued the use of parenteral narcotics by postoperative day two, with 100% off all IV narcotics by postoperative day three. This was significantly shorter than an average cessation of IV narcotic use of 3.96 days in the epidural group.

Simple linear regression was used initially to determine the impact of intercostal cryoablation on our primary outcome, hospital length of stay. There was a significant association with decreased hospital length of stay and cryoablation ($\beta = -2.33$, $R^2 = 0.89$, $p < 0.001$). This relationship was further explored with multivariate linear regression. Intercostal cryoablation was an independent predictor of decreased time in a monitored unit ($\beta = -1.92$, $R^2 = 0.54$, $p < 0.001$), hospital length of stay ($\beta = -2.41$, $R^2 = 0.68$, $p < 0.001$), reduced amount of IV narcotic use ($\beta = -52.97$, $R^2 = 0.19$, $p = 0.014$) and duration of IV narcotic use ($\beta = -1.89$, $R^2 = 0.60$, $p < 0.001$). When adjusted for covariates, cryoablation lost significance as a predictor of increased operative time ($p = 0.116$). Subset analysis comparing the seven epidural patients with local infusions catheters to the 24-cryoablation patients with local infusion catheters demonstrates that the decrease in hospital length of stay ($p = 0.0151$), decrease in time spent in a monitored

Table 2
Operative characteristics.

	Epidural ($n = 26$)	Cryoablation ($n = 26$)	*P*-value
Mean time in OR (SD)	147.9 min (27.52)	167.8 min (26.88)	0.0110
Mean surgery time (SD)	94.3 min (23.57)	114.2 min (27.91)	0.0078
Mean EBL (SD)	12.4 mL (10.32)	16.9 (8.72)	0.0933
Operative complications	0	0	1.0000
Number of Nuss bars placed			
One (%)	26 (100%)	24 (92%)	
Two (%)	0 (0%)	2 (8%)	
Local infusion catheter placed (%)	7 (27%)	24 (92%)	

OR = Operating Room, EBL = Estimated Blood Loss.

Table 3
Patient outcomes.

	Epidural ($n = 26$)	Cryoablation ($n = 26$)	*P*-value
Mean hospital discharge (SD)	5.79 days (0.93)	3.47 days (0.83)	<0.001
Time to monitored unit discharge (SD)	3.73 days (0.92)	1.88 days (0.86)	<0.001
Mean total IV narcotics** (SD)	119.8 mg (95.10)	49.03 mg (32.70)	0.0011
Mean length of IV narcotic use (SD)	3.96 days (0.96)	1.88 days (0.71)	<0.001

** Expressed in morphine equivalents.

unit ($p = 0.0054$), decreased total IV narcotic use ($p = 0151$), and the shorter time to discontinuation of IV narcotics ($p = 0.0008$) for those treated with cryoablation remain significant.

The average length of follow-up was 160 days (8–342 days) in the cryoablation group and 597 days (114–1067 days) in the epidural group (Table 4). At the initial follow-up visit, 52% of patients in both the cryoablation group and epidural group were off all narcotic pain medications. All patients in both groups had complete cessation of narcotic pain medication by the three-month routine follow-up appointment. In the cryoablation group, there were no chest wall paresthesias at the three-month follow-up visit. Three patients (12%) in the cryoablation group had displacement of their Nuss bar and required re-operation to correct the displaced bar. All these revisions occurred within 60 days of the index procedure. There were no bar displacements in the thoracic epidural group. One patient in both the cryoablation group and the epidural group had an unplanned visit to the emergency department for pain that was not controlled by their discharge medications.

3. Discussion

Pectus excavatum repair with placement of a Nuss bar has classically been associated with significant pain requiring multimodal strategies for analgesia [9,20]. The success of epidural and regional analgesia in reducing parenteral narcotic requirements supports the efficacy of a regional analgesic approach for this procedure [11]. These approaches however, do present some inherent risks; as patients may suffer from both local and systemic complications ranging from regional numbness and transient hypotension to permanent neurologic deficits [21]. There is considerable experience with using intercostal cryoablation for sustained pain control in the setting of malignant invasion of the chest wall [22], and for pain control in other thoracic operations [15,23]. The current study is the largest case series describing the outcomes of cryoablation in patients undergoing the Nuss procedure and demonstrates that cryoablation can decrease the hospital length of stay and IV narcotic use when compared to patients treated with thoracic epidurals.

Brief exposure to hypothermic conditions induces ice crystal formation in the intercostal nerves, functionally interrupting action potential transduction [16]. Additionally, reducing temperature to between −20 and −100 degrees Celsius results in axonotmesis with subsequent Wallerian degeneration of the distal axon [24]. Because the soma remains intact, this constitutes a temporary nerve injury and eventual reconstitution of the axon is expected [25]. The Atricure CryoICE® probe cools tissue to −60 degrees Celsius, thus producing a sustained but temporary sensory deficit ideal for peri- and postoperative analgesia.

The axonal degeneration secondary to cryoablative neurolysis evolves over days. Therefore, the pain relief from cryoablation is not immediate and it is imperative that patients continue to receive multimodal pain management [25]. Given this, our strategy for postoperative pain control in patients treated with cryoablation consists of a combination of IV narcotic, non-steroidal anti-inflammatory agents, anti-spasmodic agents and gabapentin in the immediate postoperative period (Fig. 3). As the full therapeutic effects of cryoablation manifest, we have noted that patients can be quickly weaned off parenteral narcotic medications. More importantly however, the use of cryoablation has completely removed epidurals and their inherent risks from our practice. While the effects of cryoablative neurolysis are temporary, patients are at risk for developing neuropathic pain as axons regenerate. To combat this, children are prescribed 300 mg of nightly gabapentin upon discharge. This is discontinued if chest wall sensation is normal at the three-month follow-up appointment. The one patient who returned to the emergency department for inadequate pain control in the cryoablation group was discharged without gabapentin and his pain improved once it was added to his regimen. This highlights the importance of the inclusion of a neuropathic analgesic as part of the pain management regimen in children treated with cryoablation.

While cryoablation does increase the surgical time by approximately 20 min, its addition to our multimodal analgesic strategy has resulted in an impressive reduction in the length of hospitalization after pectus

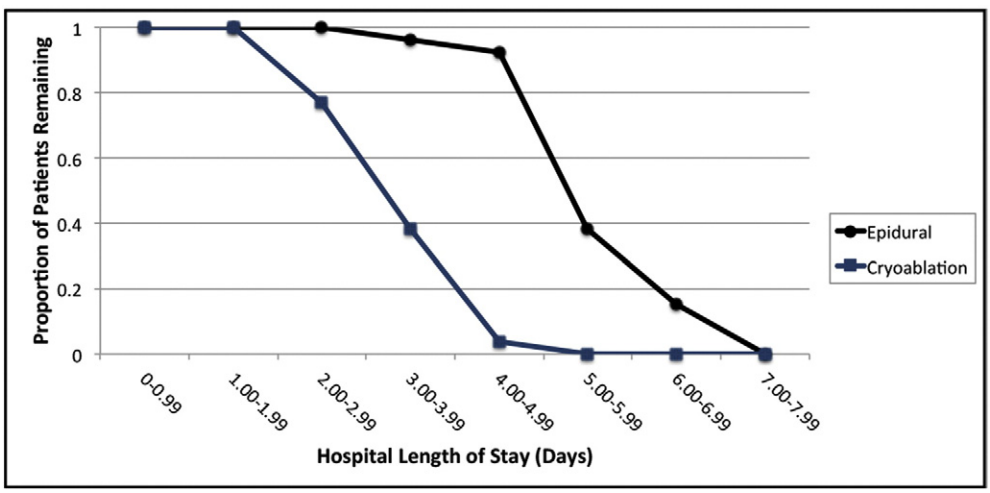

Fig. 2. Kaplan–Meier curve demonstrating the time to discharge in both the thoracic epidural group shown in black and the cryoablation group shown in blue.

Table 4
Follow-up data.

	Epidural ($n = 26$)	Cryoablation ($n = 26$)
Off narcotics at initial follow-up** (%)	13 (50%)	13 (50%)
Mean length of follow-up	597.2 days	160.1 days
Complications		
Displaced Nuss bar (%)	0 (0%)	3 (12%)
Unplanned ER visit for pain (%)	1 (4%)	1 (4%)

** Mean initial follow-up epidural = 26.7 days; cryoablation = 17.5 days.

excavatum repair when compared to patients treated with thoracic epidurals. This reduction in hospital length of stay more than offsets the additional cost of the increased operating room time and the cost of cryoablation. Furthermore, as experience with cryoablation improves, operative times should decrease.

While this case series demonstrates the potential benefits of intercostal nerve cryoablation in patients undergoing pectus excavatum repair, it suffers from several limitations. The retrospective nature of the study and lack of rigorous, standardized treatment protocols in both the cryoablation and epidural groups prohibit a comparative analysis demonstrating the true benefits of cryoablation. In addition, the short follow-up period limits the ability to detect long-term complications associated with cryoablative therapy. Lastly the small sample size may not be adequate to detect the presence of rare complications.

One of our initial concerns in utilizing this therapy was that by removing most of the pain sensation after the procedure, patients might be inclined to ignore activity restrictions, increasing the risk of Nuss bar displacement. Our data supports this hypothesis with three (12%) of 26 cryoablation patients requiring re-intervention for bar displacement compared to none of the patients who had thoracic epidurals placed for pain management. The three patients that had bar displacement in this series were all revised with a simple operation without repeat thoracoscopy or cryoablation. Aside from the addition of cryoablation, there were no other technical changes to the procedure, which could account for this increase in bar displacements. Since pain can be protective, in the sense that if it hurts when you do an activity you are less likely to do that activity, we feel that bar displacement should be viewed as an additional endpoint in the cryoablation group. We recommend conducting a prospective trial to see if this effect persists. No other complications specific to cryoablation including neuralgias, pneumothorax, soft tissue injury or vascular injury were identified.

In our retrospective, multi-institutional study we have shown that use of cryoablation of the third through seventh intercostal nerves bilaterally has resulted in excellent pain control and has significantly decreased our use of IV narcotics. Given the improvement in pain control and overall length of stay demonstrated in this study when compared to patients managed with thoracic epidurals, intercostal nerve cryoablation has changed our paradigm for pain management. This has not only improved the quality of care that our patients receive but may also decrease healthcare resource utilization and the overall financial burden of the disease. A prospective, randomized controlled trial comparing the outcomes of cryoablation to those of traditional postoperative pain management strategies would help to further support this practice.

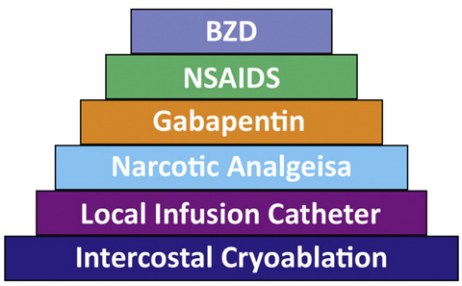

Fig. 3. While intercostal cryoablation therapy serves as the foundation for our postoperative pain management strategy, several analgesic adjuncts including local infusion catheters, narcotics, gabapentin, NSAIDS, and benzodiazepines are used. This multimodal strategy has been designed to minimize narcotic use while optimizing pain relief. (NSAIDS = non-steroidal anti-inflammatory drugs, BZD = benzodiazepine).

Author contribution form (*)

Each author should have participated sufficiently in the work to take public responsibility for appropriate portions of the manuscript contents. Allowing one's name to appear as an author without contributing significantly to the study or adding the name of an individual that has not contributed or has not agreed to the study in its current form is considered a breach of appropriate authorship and publication ethics. No individual other than the authors listed below should have contributed substantially to the preparation and revision of the manuscript. Ghostwriting is not acceptable. Individuals who do not meet the criteria for authorship can be recognized and listed in the acknowledgments. This includes individuals that allow their clinical experience to be included in the study, those that provide only technical assistance, copyediting, proofreading or translation assistance, or a departmental leader that provided only general support including a department Chair.

For multi-institutional studies, groups of individuals and institutions that have materially contributed to the study but, whose contributions do not justify authorship may be listed in an appendix under a heading such as participating or clinical investigators. Their function should be described for example as a scientific advisor, critically reviewed the study proposal or participating institution.

Type the name of each author next to the appropriate following categories:

Study conception and design: Benjamin Keller, Sandra Kabagambe, James Becker, Julia Clark-Wronski, Kenneth Furukawa, Rebecca Stark, Amy Rahm, Shinjiro Hirose, Gary Raff.

Data acquisition: Benjamin Keller, Sandra Kabagambe, Y. Julia Chen, Laura Goodman,

Analysis and data interpretation: Benjamin Keller, James Becker.

Drafting of the manuscript: Benjamin Keller, James Becker.

Critical revision: Benjamin Keller, Sandra Kabagambe, James Becker, Y. Julia Chen, Laura Goodman, Julia Clark-Wronski, Kenneth Furukawa, Rebecca Stark, Amy Rahm, Shinjiro Hirose, Gary Raff.

Submit this form with the manuscript.

(*): Modified from the authorship requirements of the J Am Coll Surg.

References

[1] Fokin AA, Steuerwald NM, Ahrens WA, et al. Anatomical, histologic, and genetic characteristics of congenital chest wall deformities. Semin Thorac Cardiovasc Surg 2009;21:44–57.
[2] Kelly Jr RE, Cash TF, Shamberger RC, et al. Surgical repair of pectus excavatum markedly improves body image and perceived ability for physical activity: multicenter study. Pediatrics 2008;122:1218–22.
[3] Nuss D, Kelly Jr RE. Minimally invasive surgical correction of chest wall deformities in children (Nuss procedure). Adv Pediatr Infect Dis 2008;55:395–410.
[4] Ravitch MM. The operative treatment of pectus excavatum. Ann Surg 1949;129:429–44.
[5] Nuss D, Kelly Jr RE, Croitoru DP, et al. A 10-year review of a minimally invasive technique for the correction of pectus excavatum. J Pediatr Surg 1998;33:545–52.
[6] Nasr A, Fecteau A, Wales PW. Comparison of the Nuss and the Ravitch procedure for pectus excavatum repair: a meta-analysis. J Pediatr Surg 2010;45:880–6.
[7] Papic JC, Finnell SM, Howenstein AM, et al. Postoperative opioid analgesic use after Nuss versus Ravitch pectus excavatum repair. J Pediatr Surg 2014;49:919–23 [discussion 923].
[8] Loftus PD, Elder CT, Russell KW, et al. Paravertebral regional blocks decrease length of stay following surgery for pectus excavatum in children. J Pediatr Surg 2016;51:149–53.
[9] Singhal NR, Jones J, Semenova J, et al. Multimodal anesthesia with the addition of methadone is superior to epidural analgesia: a retrospective comparison of intraoperative anesthetic techniques and pain management for 124 pediatric patients undergoing the Nuss procedure. J Pediatr Surg 2016;51:612–6.

[10] Stroud AM, Tulanont DD, Coates TE, et al. Epidural analgesia versus intravenous patient-controlled analgesia following minimally invasive pectus excavatum repair: a systematic review and meta-analysis. J Pediatr Surg 2014;49:798–806.
[11] Hall Burton DM, Boretsky KR. A comparison of paravertebral nerve block catheters and thoracic epidural catheters for postoperative analgesia following the Nuss procedure for pectus excavatum repair. Paediatr Anaesth 2014;24:516–20.
[12] Lukosiene L, Rugyte DC, Macas A, et al. Postoperative pain management in pediatric patients undergoing minimally invasive repair of pectus excavatum: the role of intercostal block. J Pediatr Surg 2013;48:2425–30.
[13] St Peter SD, Weesner KA, Weissend EE, et al. Epidural vs patient-controlled analgesia for postoperative pain after pectus excavatum repair: a prospective, randomized trial. J Pediatr Surg 2012;47:148–53.
[14] Trescot AM. Cryoanalgesia in interventional pain management. Pain Phys 2003;6:345–60.
[15] Nelson KM, Vincent RG, Bourke RS, et al. Intraoperative intercostal nerve freezing to prevent postthoracotomy pain. Ann Thorac Surg 1974;18:280–5.
[16] Moorjani N, Zhao F, Tian Y, et al. Effects of cryoanalgesia on post-thoracotomy pain and on the structure of intercostal nerves: a human prospective randomized trial and a histological study. Eur J Cardiothorac Surg 2001;20:502–7.
[17] Koethe Y, Mannes AJ, Wood BJ. Image-guided nerve cryoablation for post-thoracotomy pain syndrome. Cardiovasc Intervent Radiol 2014;37:843–6.
[18] Byas-Smith MG, Gulati A. Ultrasound-guided intercostal nerve cryoablation. Anesth Analg 2006;103:1033–5.
[19] Kim S, Idowu O, Palmer B, et al. Use of transthoracic cryoanalgesia during the Nuss procedure. J Thorac Cardiovasc Surg 2016;151:887–8.
[20] Mavi J, Moore DL. Anesthesia and analgesia for pectus excavatum surgery. Anesthesiol Clin 2014;32:175–84.
[21] Giebler RM, Scherer RU, Peters J. Incidence of neurologic complications related to thoracic epidural catheterization. Anesthesiology 1997;86:55–63.
[22] Sloan PA. The evolving role of interventional pain management in oncology. J Support Oncol 2004;2:491–500 [503].
[23] Moore W, Kolnick D, Tan J, et al. CT guided percutaneous cryoneurolysis for post thoracotomy pain syndrome: early experience and effectiveness. Acad Radiol 2010;17:603–6.
[24] Evans PJ, Lloyd JW, Green CJ. Cryoanalgesia: the response to alterations in freeze cycle and temperature. Br J Anaesth 1981;53:1121–7.
[25] Whittaker DK. Degeneration and regeneration of nerves following cryosurgery. Br J Exp Pathol 1974;55:595–600.